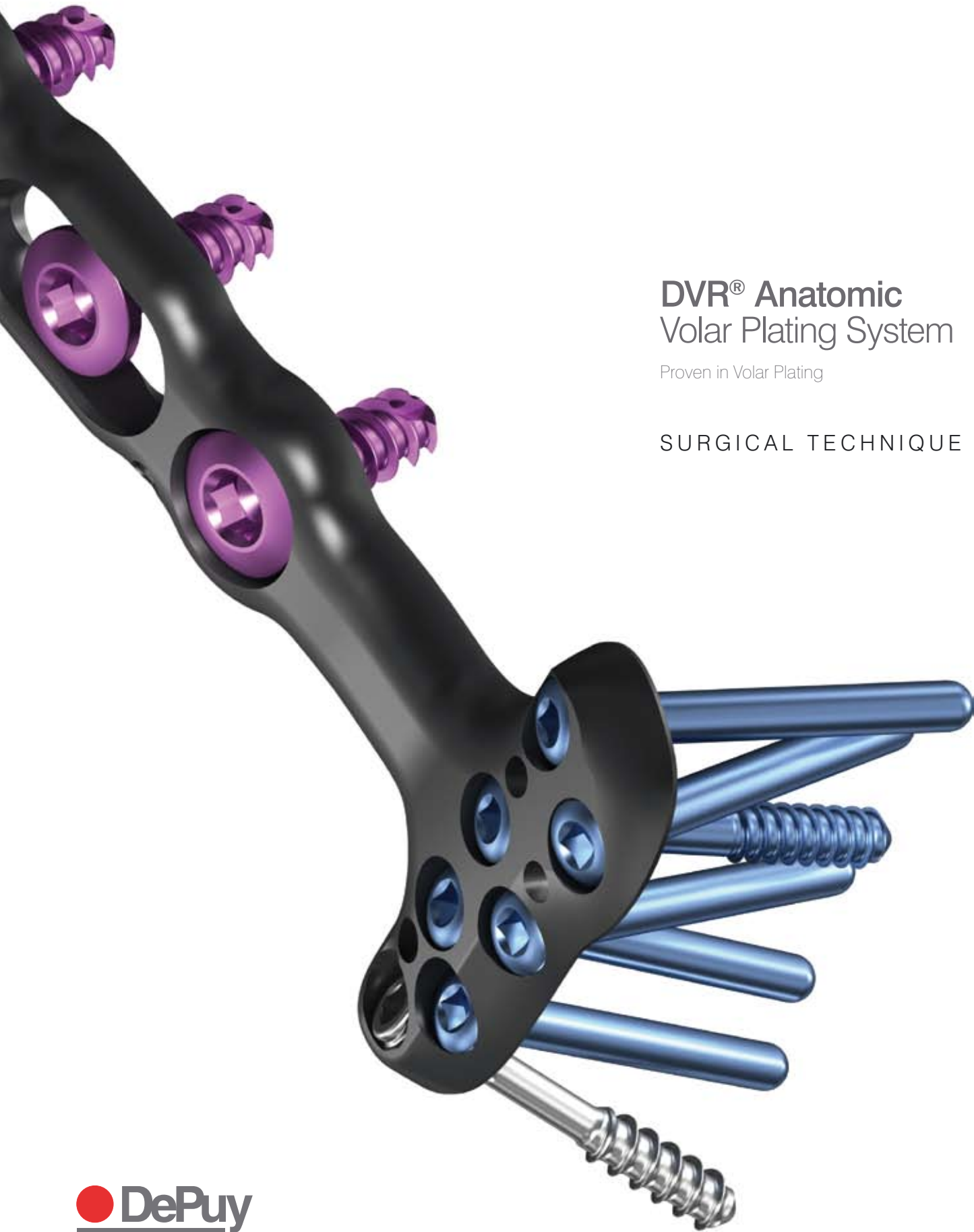
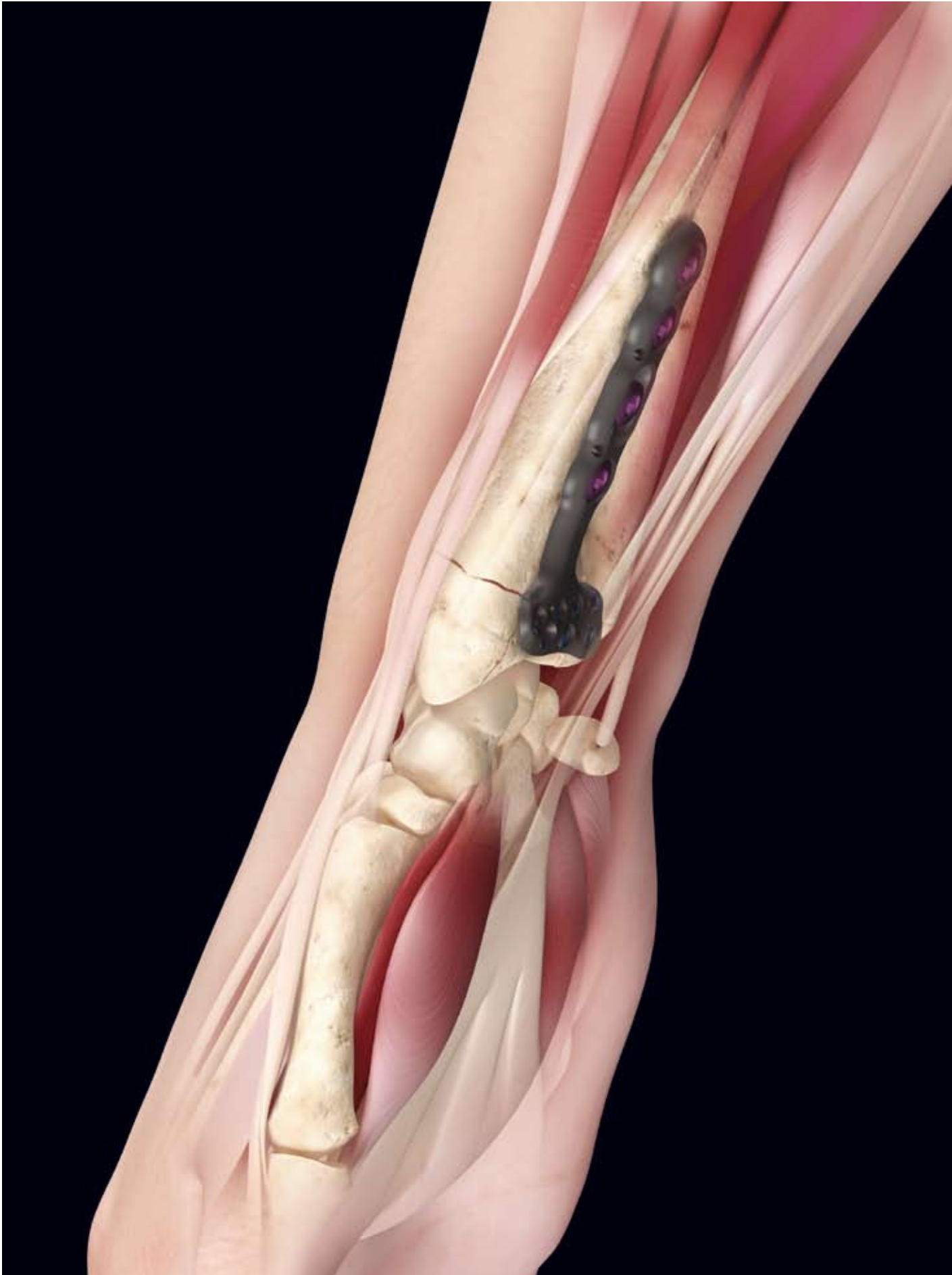


# DVR<sup>®</sup> Anatomic Volar Plating System

Proven in Volar Plating

SURGICAL TECHNIQUE



# Introduction

The DVR® Anatomic Volar Plating system builds on the success of the original DVR® by introducing several improvements that make the procedure easier and more reproducible.

## DVR® Anatomic Volar Plating System Highlights

- Provides stable internal fixation for the treatment of most fractures and deformities of the distal radius.
- Is placed on the volar aspect of the distal radius to help prevent tendon complications and preserve dorsal tissues.
- Acts as a template to aid in reduction through indirect means by applying traction, ligamentotaxis and direct pressure over the dorsal aspect of the distal radius.
- Has anatomically distributed subchondral support pegs to secure the distal fragments.
- Secures distal fragments with anatomically distributed subchondral support pegs.
- Is available in multiple plate sizes and screw options to provide intra-operative flexibility.

## **Clinical Indications**

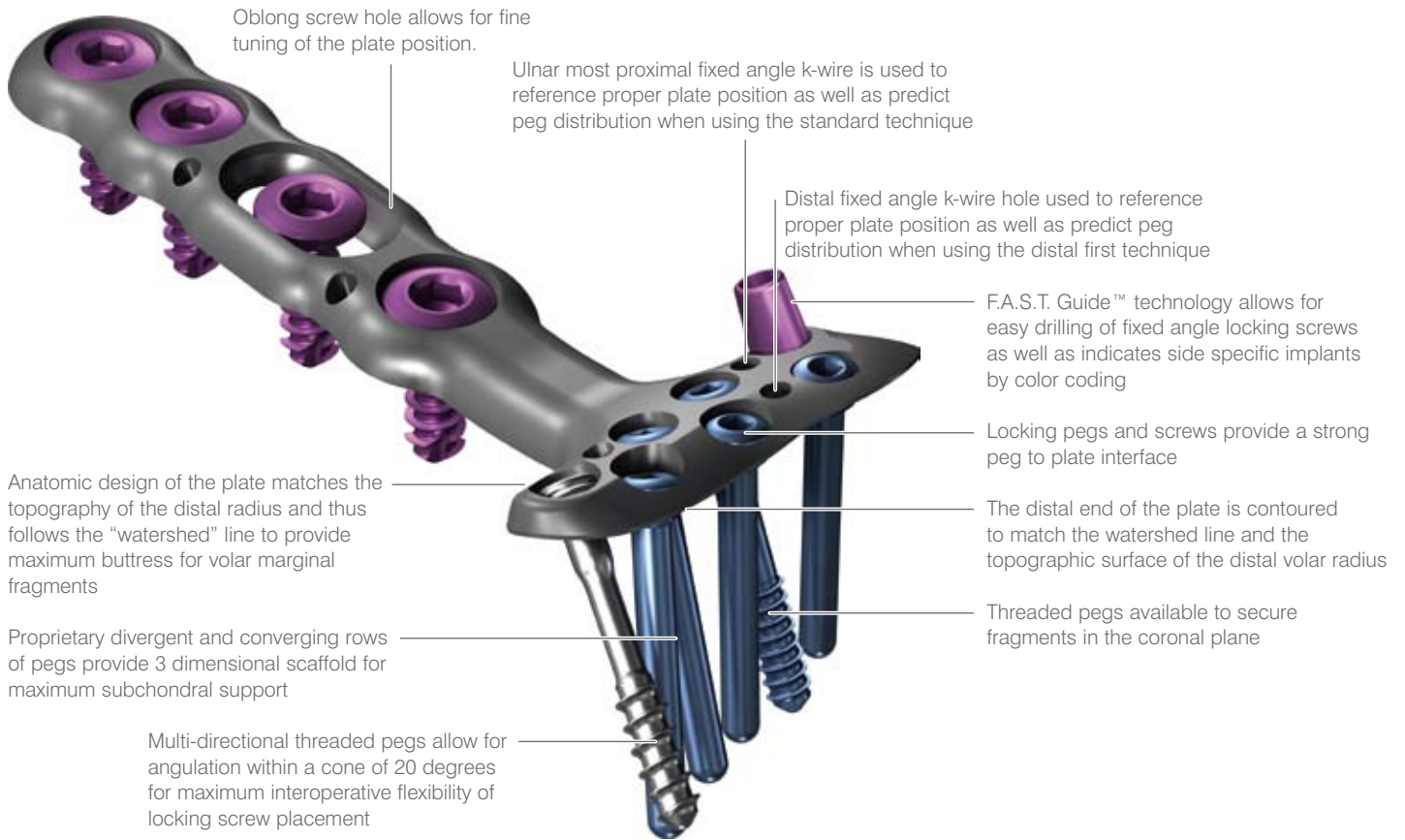
The DVR® Anatomic Plate is intended for the fixation of fractures and osteotomies involving the distal radius.

## **Surgical Approaches**

Simple and acute fractures can be treated through the standard Flexor Carpi Radialis (FCR) approach.

Intra-articular fractures, nascent malunions and established malunions are best managed through the extended form of the FCR approach.

# DVR<sup>®</sup> Anatomic Volar Plating System



Available plate sizes and lengths listed on page 18.

## Screws and Pegs

Screws/Pegs	Available Lengths
Smooth Pegs (Locking)	10, 12, 14, 16, 18, 20, 22, 24, 26, 28 and 30 mm
Partially Threaded Pegs (Locking)	10, 12, 14, 16, 18, 20, 22, 24, 26, 28 and 30 mm
Multi Directional Threaded Pegs (Locking)	10, 12, 14, 16, 18, 20, 22, 24, 26, 28 and 30 mm
Cortical Bone Screws	10, 12, 13, 14, 15, 16, 18 and 20 mm

# FCR Approach

## Incision

Make an incision approximately 8 cm long over the course of the flexor carpi radialis (FCR) tendon.

A zigzag incision is made across the wrist flexion creases to allow better access and visualisation. (Figure 1)

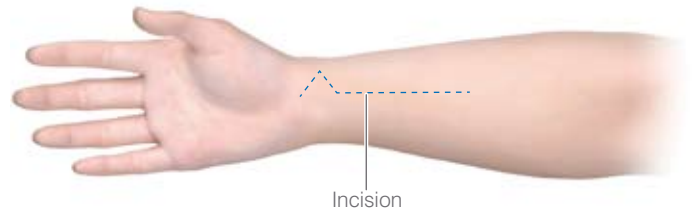


Figure 1

## Release the Flexor Carpi Radialis (FCR) Tendon Sheath

Expose and open the sheath of the FCR tendon. (Figure 2)

Dissect the FCR tendon distally to the level of the superficial radial artery.

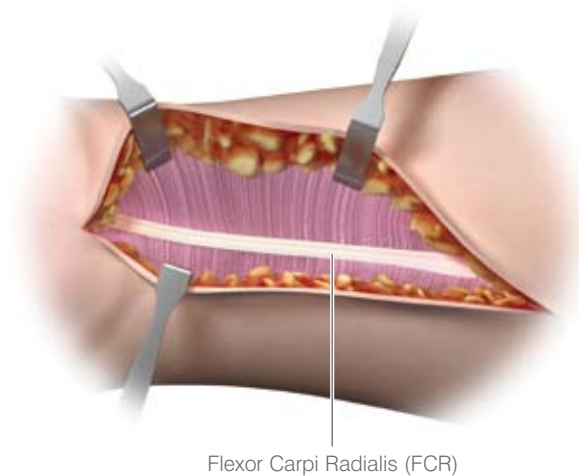


Figure 2

## Crossing the Deep Fascia

Retract the FCR tendon towards the ulna while protecting the median nerve. (Figure 3)

Incise through the floor of the FCR sheath to gain access to the deeper levels.

Split the sheath of the FCR tendon distally up to the tuberosity of the scaphoid.

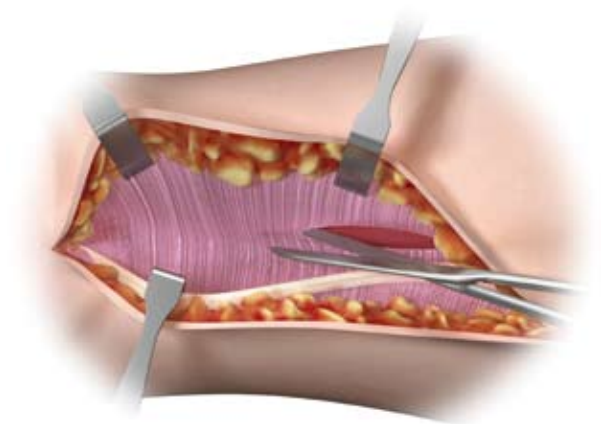


Figure 3

# FCR Approach

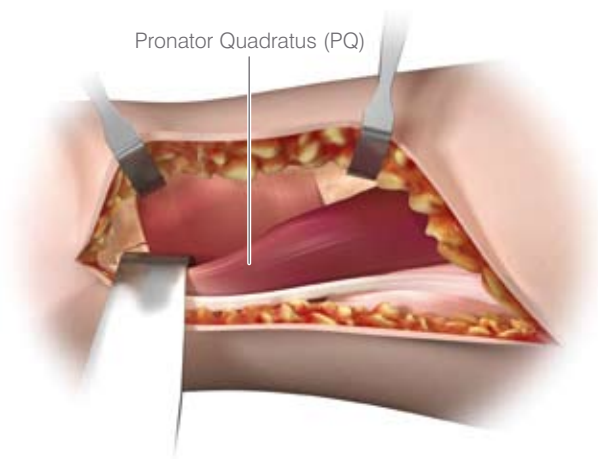


Figure 4

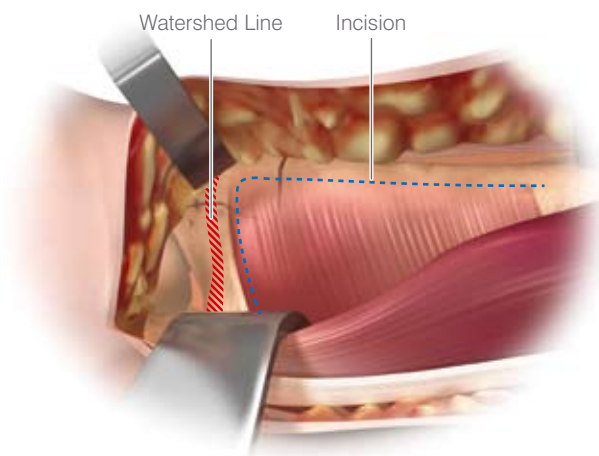


Figure 5

## Mid-Level Dissection

Develop the plane between the flexor pollicis longus (FPL) and the radial septum to reach the surface of the radius.

Develop widely the subtendinous space of parona and expose the pronator quadratus (PQ). (Figure 4)

## Identifying the Watershed Line

Palpate the radius distally to identify the volar rim of the lunate fossa. This establishes the location of the watershed line. (Figure 5)

The transitional fibrous zone (TFZ) is a 1 cm wide band of fibrous tissue located between the watershed line and the PQ that must be elevated to properly visualise the fracture.

Release the PQ by sharply incising over the watershed line and proximally on the lateral edge of the radius. (Figure 5)

### **Elevating the Pronator Quadratus (PQ)**

Use a periosteal elevator to elevate the PQ to expose the volar surface of the radius. (Figure 6)

The fracture line on the volar cortex is usually simple, facilitating reduction.

The origin of the FPL muscle can be partially released for added exposure.

*Note: The pronator quadratus is frequently ruptured.*

*Caution: Do not open the volar wrist capsule. Doing so may cause devascularization of the fracture fragments and destabilization of the volar wrist ligaments.*

### **The Radial Septum**

Near the radial styloid process, the radial septum becomes a complex fascial structure which includes the first extensor compartment, the insertion of the brachioradialis and the distal part of the FCR tendon sheath. (Figure 7)

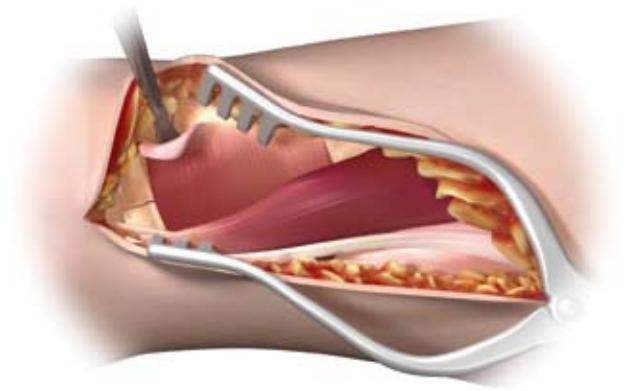


Figure 6

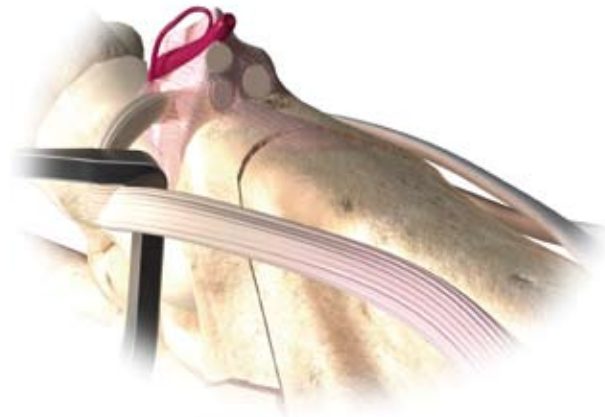

Figure 7

# FCR Approach

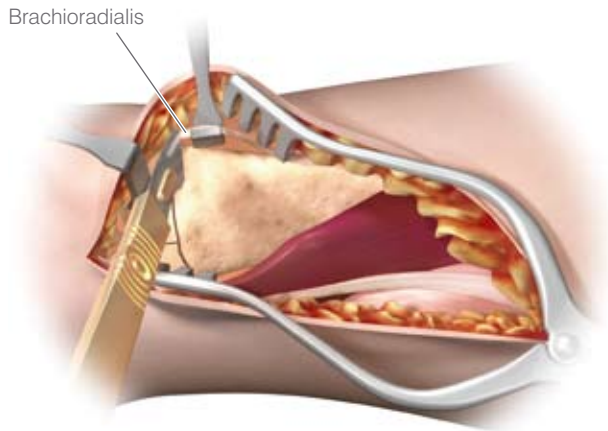


Figure 8

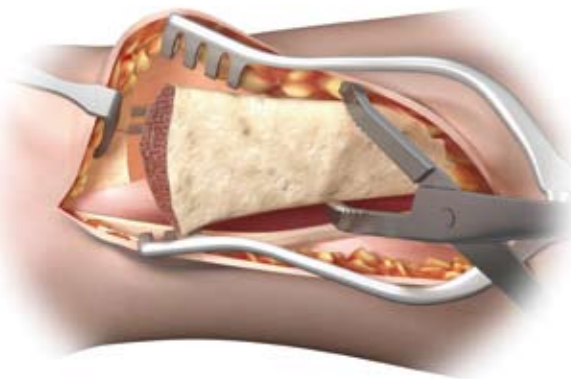


Figure 9

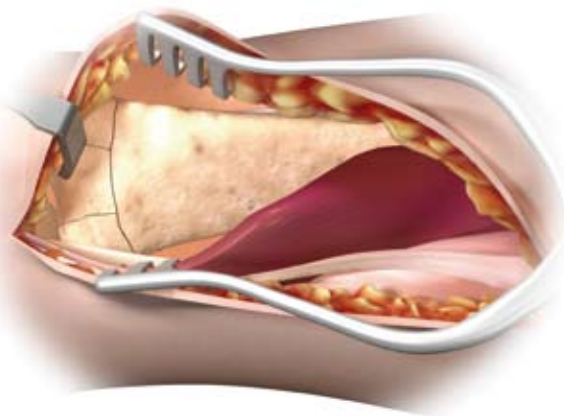


Figure 10

## Release of the Distal Fragment

Release the insertion of the brachioradialis which is found on the floor of the first compartment in a step cut fashion. (Figure 8)

*Note: The brachioradialis is the prime deforming force of the distal fragment.*

Identify and retract the APL and EPB tendons.

*Note: Care should be taken to protect the radial artery.*

## The Extended FCR Approach

Pronation of the proximal fragment out of the way provides exposure to the dorsal aspect of the fracture allowing fracture debridement and reduction.

## Intra-Focal Exposure

Intra-focal exposure is obtained by pronating the proximal fragment out of the way. A bone clamp facilitates this maneuver. (Figure 9)

Preserve the soft tissue attachments to the medial aspect of the proximal fragment.

*Note: This is where the anterior interosseous vessels that feed the radial shaft are located.*

## Provisional Fracture Reduction

After fracture debridement, supinate the proximal radius back into place and restore radial length by reducing the volar cortex. (Figure 10)

# Proximal Plate Positioning

Decide the correct position for the plate by judging how the plate conforms to the watershed line and the volar surface of the radius.

Using the 2.5 mm bit, drill through the proximal oblong hole of the plate, which will allow for plate adjustments. (Figure 11)

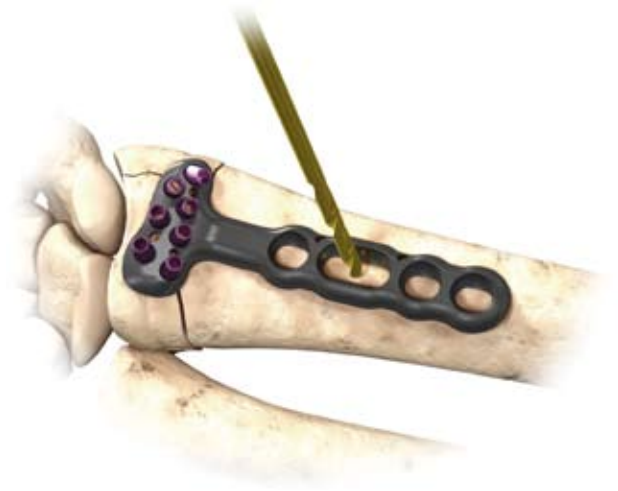


Figure 11

Measure the required screw depth using the flat side of the Depth Gauge. (Figure 12)

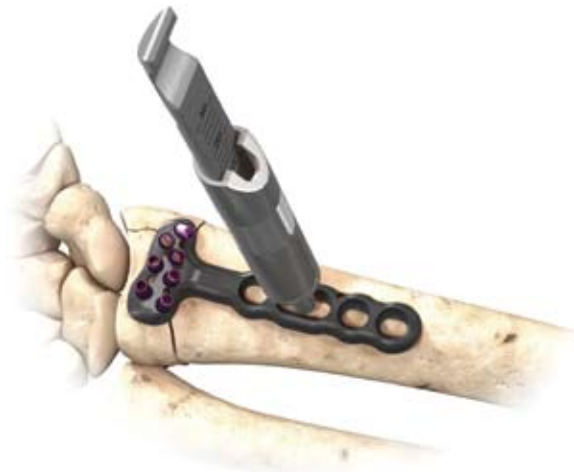

Figure 12

Insert the appropriate length cortical screw. (Figure 13)

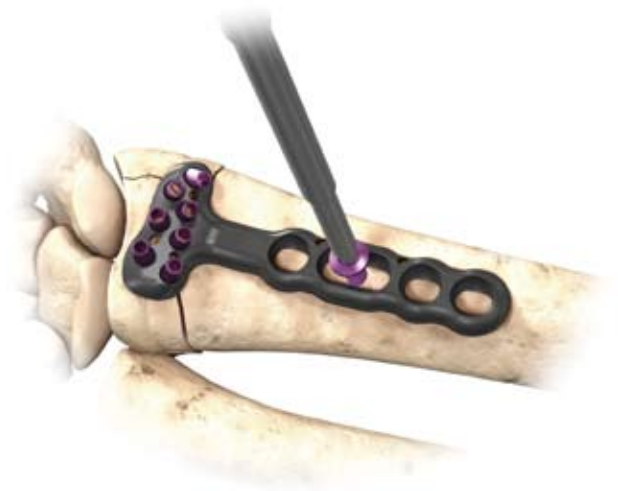


Figure 13

# Distal Plate Fixation

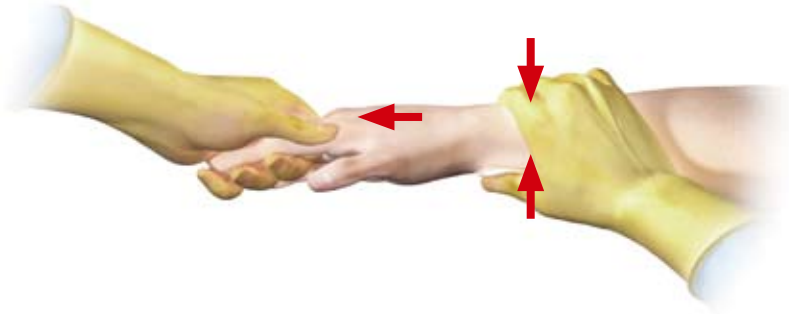


Figure 14

## Final Fracture Reduction

Final reduction is obtained by indirect means using the DVR® Anatomic Plate as a template, then applying traction, ligamentotaxis and direct pressure over the dorsal aspect. (Figure 14)

*Note: A properly applied bolster helps to maintain the reduction.*

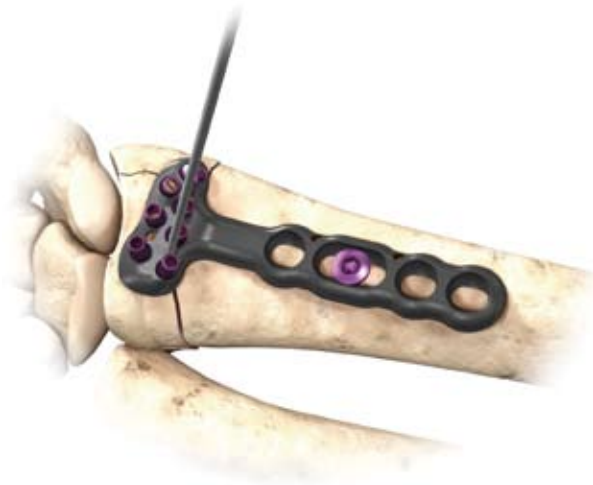

Figure 15

## Distal Plate Fixation

First, secure the distal fragment to the plate by inserting a k-wire through the most ulnar k-wire hole on the proximal row. (Figure 15) Proper plate positioning can be confirmed by obtaining a 20 degree lateral. The k-wire should be 2–3 mm subchondral to the joint line on this view.

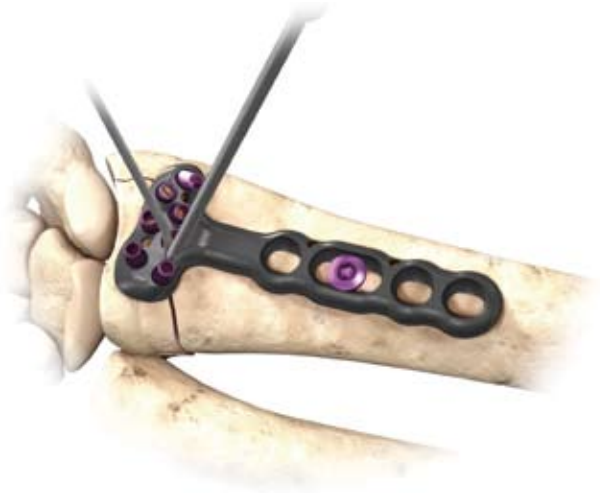

Figure 16

## Drilling the Proximal Rows

Using a 2.0 mm bit, drill through the proximal single-use F.A.S.T. Guide™ starting on the ulnar side in order to stabilise the lunate fossa. (Figure 16)

*Note: Bend the K-wire out of the way to facilitate drilling.*

### Gauging Through the F.A.S.T. Guide™

Assess carefully the length of the proximal row pegs with the appropriate side of the depth gauge. (Figure 17)

*Caution: avoid excessive peg length as this can potentially cause extensor tendon irritation.*

*Note: if the F.A.S.T. Guide™ is removed before gauging the screw depth, use the scale on the flat side of the depth gauge.*

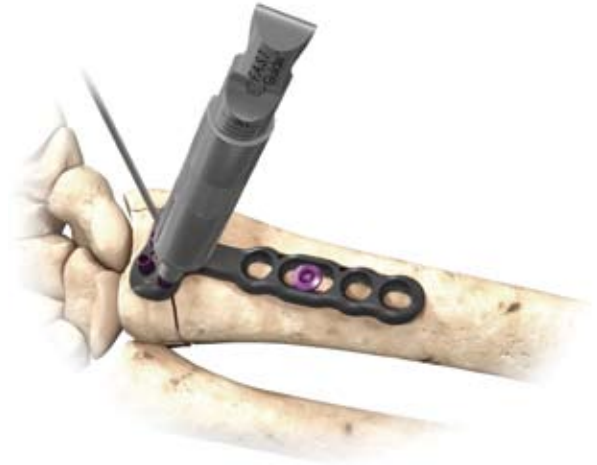

Figure 17

### Proximal Peg Placement

Remove each F.A.S.T. Guide™ with the peg driver after checking the drilled depth. (Figure 18)

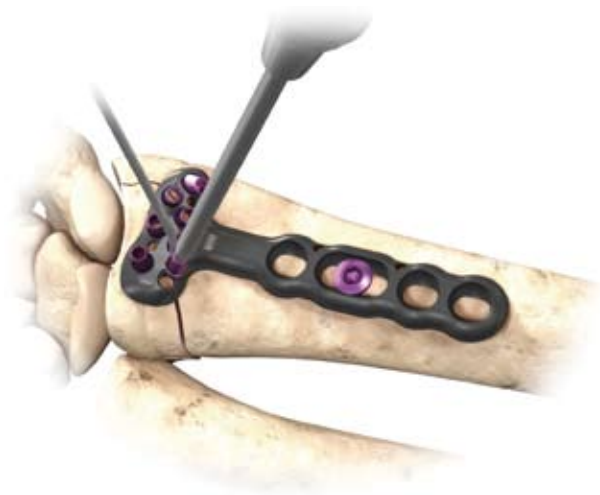

Figure 18

Using the same peg driver, fill the peg holes with the appropriate length peg. (Figure 19)

*Note: The use of threaded pegs will help to capture dorsal comminuted fragments. The fully threaded pegs (FP) are NOT intended for use with the DVRA plates.*

*Caution: Do not permanently implant K-wires through the holes of the plate as they may back out and cause tissue damage.*

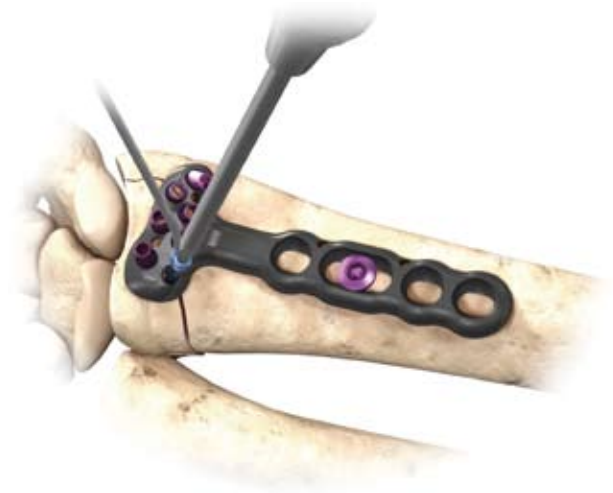

Figure 19

# Final Proximal Plate Fixation

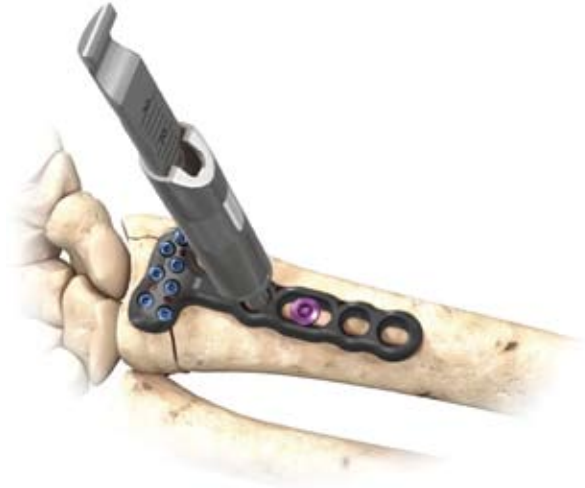

Figure 20

## Final Plate Fixation

Fill all the holes of the distal peg row.

As the distal row converges on the proximal row at between 16 mm and 18 mm, an 18 mm length peg is all that is needed in the distal row.

Apply the remaining proximal cortical screws. (Figure 20) SP series screws are not intended to provide subchondral support and use should be limited to capture of remote bone fragments where partially threaded pegs can not be used.

*Note: The proximal row of pegs provides support to the dorsal aspect of the articular surface. The distal row of pegs provides support to the central and volar aspects of the subchondral plate.*

*Remove all F.A.S.T. Guide™ even if the peg hole is not used.*

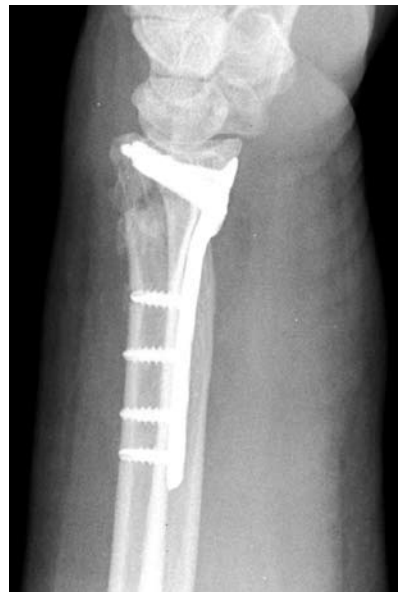
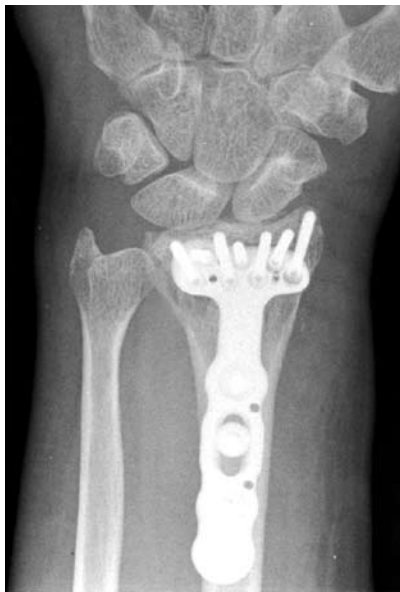
Figure 21

## Final Radiographs

A 20° – 30° elevated lateral fluoroscopic view allows visualisation of the articular surface, evaluation of volar tilt, and confirmation for proper peg placement 2 – 3 mm proximal to the subchondral plate. (Figure 21)

To confirm that the length of each individual peg is correct, pronate and supinate the wrist under fluoroscopy.

# Final Appearance

## Final Appearance

A properly applied plate should be just proximal to the watershed line and not project above or beyond it in order to avoid contact with the flexor tendons. (Figure 22)

## Wound Closure

Repair the IFZ in order to cover the distal edge of the DVR® Anatomic Plate.

Repair the brachioradialis in a side-to-side fashion.

Suture the PQ to the IFZ and the repaired brachioradialis.

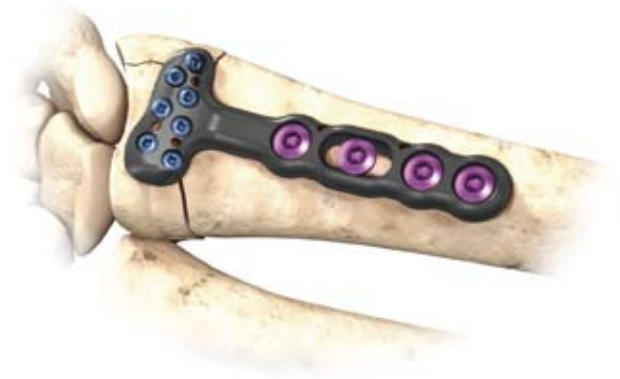
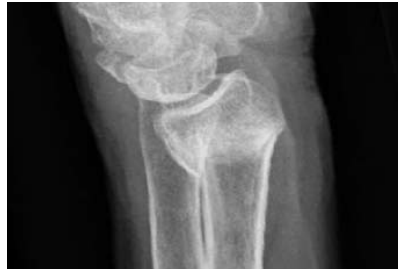
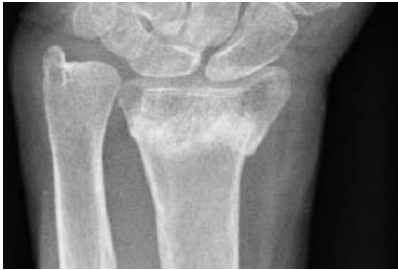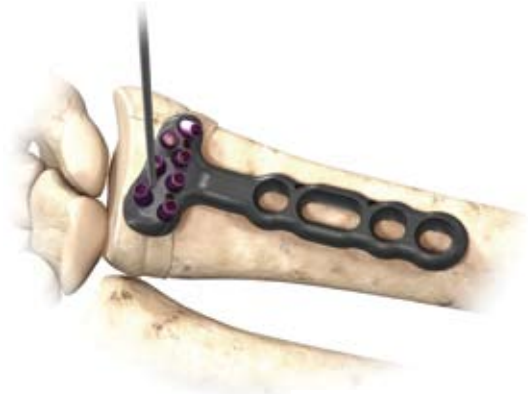Figure 22

# Distal Fragment First Technique For Established Malunions

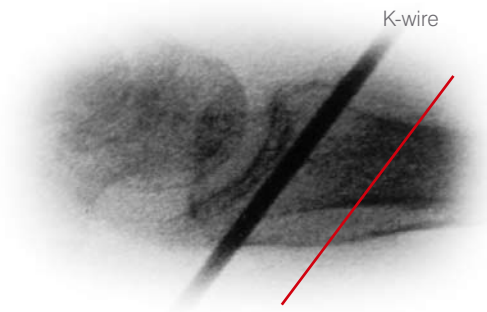

Complete exposure and place a K-wire 2 – 3 mm proximal to the articulating surface and parallel to the joint line.



*Note: Use the K-wire hole on the distal row of the DVR® Anatomic Plate as a guide for proper K-wire placement. (Figure 23)*

Figure 23



Osteotomy Plane

Figure 24

Create the osteotomy plane parallel to the K-wire. (Figure 24)




Figure 25

Release the brachioradialis, then pronate the radius and release the dorsal periosteum. (Figure 25)

*Note: The location of the distal peg rows can be identified and drilled prior to the osteotomy.*

Supinate the proximal fragment and slide the DVR® Anatomic Plate over the K-wire. (Figure 26) The K-Wire will assure proper restoration of volar tilt.



Figure 26

Fix the DVR® Anatomic Plate to the distal fragment. (Figure 27) The watershed line provides guidance for proper radiolunate deviation.

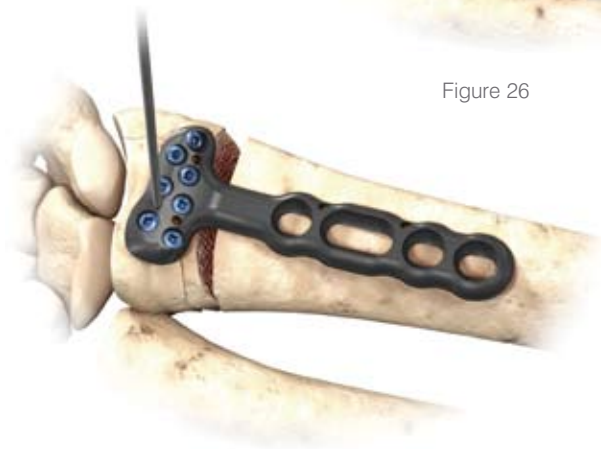

Figure 27

Once distal fixation is complete, the tail of the implant is secured to the shaft of the radius to re-create the 12 degrees of normal volar tilt.



Figure 28

After fixation, autograft is applied and the wound closed. (Figure 29)

Confirm postoperative results with radiographs.

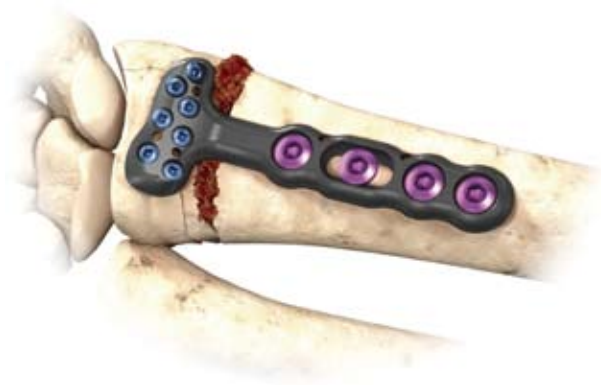
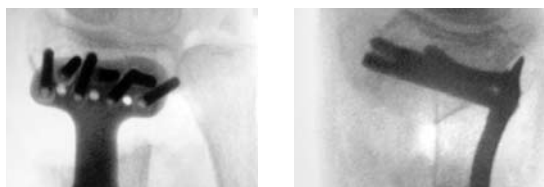
Figure 29

# Installation of Multi Directional Threaded Peg

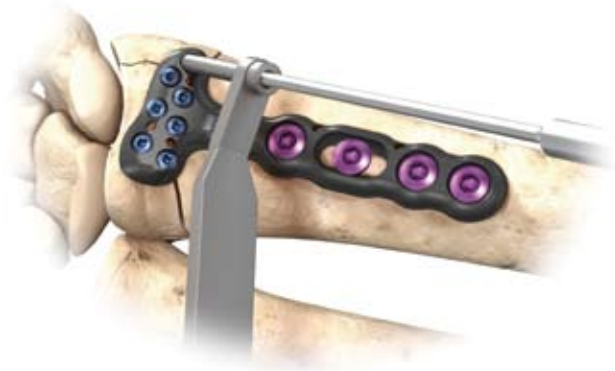

Figure 30



Figure 31

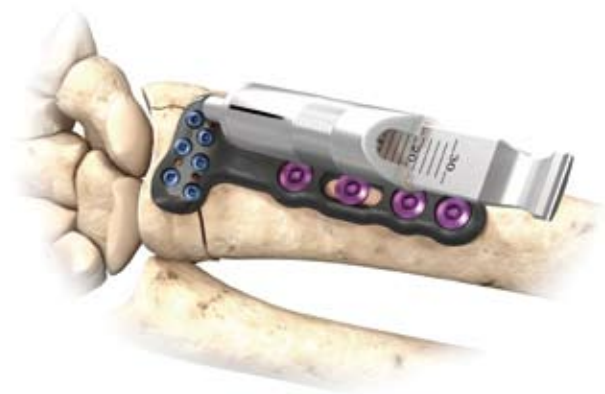

Figure 32

Ensure that the fixed-angle pegs have been installed prior to installing the MDTP.

Remove the F.A.S.T. Guide™ using the peg driver.

Place the 2.0 mm end of the Soft Tissue Guide (STG) into the radial styloid and/or the most ulnar hole in the proximal row of the DVR Anatomic plate.

*Note: The MDTPs are not recommended for the distal row.*

Place the 2.0 mm drill bit through the STG until it comes in contact with the bone. Determine the trajectory of the drill bit by varying the angle of the STG and drill (Figure 30). The MDTP's can be successfully installed within a cone of 20 degrees off of the fixed angle trajectory.

Assemble the Multi Direct 2.0 mm insert into the modular handle, verifying that it is firmly attached. (Figure 31)

Measure the depth of the hole using the flat side of the F.A.S.T. Bone Depth Gauge (FBDG). (Figure 32)

Load the appropriately sized MDTP into the driver.  
The peg should grip the driver. (Figure 33)



Figure 33

Install the MDTP into the pre-drilled hole. Be careful to keep the driver fully engaged with the peg. Install the peg firmly until increased torque yields in no further rotation. (Figure 34)

*Note: For best results, use a new Multi Direct insert for each surgery. If necessary, after installation the MDTP can be removed and reinstalled to further improve positioning.*

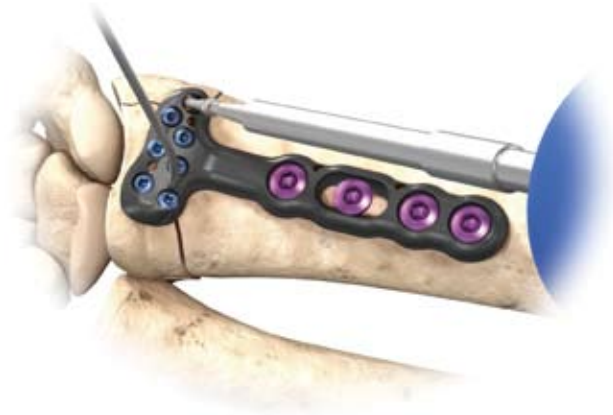

Figure 34

# Ordering Information

## Pegs and Screws



**Smooth Peg, Locking**  
Provides subchondral support

10 mm – 30 mm lengths (2 mm steps)



**Threaded Peg, Locking**  
Distal threads to capture and lag fragments

10 mm – 30 mm lengths (2 mm steps)



**Multi Directional Threaded Peg**  
Provides interoperative freedom to vary the trajectory of a fixed angle locking trajectory within a cone of 20 degrees.

10 mm – 30 mm lengths (2 mm steps)



**Screws, Non-Locking**  
Fully threaded to anchor fragments for added fixation

10 mm – 30 mm lengths (2 mm steps)



**Cortical Screws**  
Provide bicortical fixation for proximal fragments

10,12,13,14,15,16, 18 and 20 mm

## DVR® Anatomic Plates

**Narrow Short:**  
22.0 mm x 57.0 mm  
DVRANS L  
DVRANS R



**Wide Standard:**  
31.5 mm x 62.7 mm  
DVRAW L  
DVRAW R



**Standard Short:**  
24.4 mm x 51.0 mm  
DVRAS L  
DVRAS R



**Standard:**  
24.4 mm x 56.6 mm  
DVRA L  
DVRA R



**Standard Extended:**  
24.4 mm x 89.0 mm  
DVRAX L  
DVRAX R



**Standard Extra Extended:**  
24.4 mm x 175.0 mm  
DVRAXX L  
DVRAXX R





DVR® Anatomic Plate Modular Tray

---

New fully modular tray system addresses multiple applications with the use of a single tray

- Reduced OR Instruments
- Improved Workflow









# DVR<sup>®</sup> Anatomic Plate

EPI date: 1/21/08

## Important

This Essential Product Information sheet does not include all of the information necessary for selection and use of a device. Please see full labelling for all necessary information.

## Indications (DVR<sup>®</sup> Anatomic and DNP<sup>®</sup> Anatomic Systems)

The Distal Radius Fracture Repair System is intended for the fixation of fractures and osteotomies involving the distal radius.

## Indications (Fragment Plate System)

The Fragment Plate System is intended for essentially non-load bearing stabilization and fixation of small bone fragments in fresh fractures, revision procedures, joint fusion and reconstruction of small bones of the hand, foot, wrist, ankle, humerus, scapula, finger, toe, pelvis and craniomaxillofacial skeleton.

## Contraindications

If any of the following are suspected, tests are to be performed prior to implantation. Active or latent infection. Sepsis. Insufficient quantity or quality of bone and/or soft tissue. Material sensitivity. Patients who are unwilling or incapable of following post operative care instructions.

## Warning and Precautions

Although the surgeon is the learned intermediary between the company and the patient, the important information conveyed in this document should be conveyed to the patient. The patient must be cautioned about the use, limitations and possible adverse effects of these implants. The patient must be warned that failure to follow postoperative care instructions may cause the implant or treatment to fail.

An implant must never be reused. Previous stresses may have created imperfections that can potentially lead to device failure. Protect implant appliances against scratching or nicking. Such stress concentration can lead to failure.

Orthopaedic instrumentation does not have an indefinite functional life. All re-usable instruments are subjected to repeated stresses related to bone contact, impaction, routine cleaning and sterilization processes. Instruments should be carefully inspected before each use to ensure that they are fully functional. Scratches or dents can result in breakage. Dullness of cutting edges can result in poor functionality. Damaged instruments should be replaced to prevent potential patient injury such as metal fragments into the surgical site. Care should be taken to remove any debris, tissue or bone fragments that may collect on the instrument. Most instrument systems include inserts/trays and a container(s). Many instruments are intended for use with a specific implant system. It is essential that the surgeon and operating theatre staff are fully familiar with the appropriate surgical technique for the instruments and associated implant, if any.

- Do NOT open the volar wrist capsule. Doing so may cause devascularisation of the fracture fragments and destabilisation of the volar wrist ligaments.
- If necessary, contour the DVR<sup>®</sup> Anatomic plate in small increments. Excessive contouring may weaken or fracture the plate.
- Exercise care when bending the fragment plates to avoid weakening or fracture of the plates.
- Ensure removal of all F.A.S.T. Guide™ inserts after use.
- Do NOT use fully threaded pegs (FP) with the DVR<sup>®</sup> Anatomic and DNP<sup>®</sup> Anatomic plates. The fully threaded pegs (FP) are designed for use with the fragment plates.
- Do NOT use peg/screw lengths that will excessively protrude through the far cortex. Protrusion through the far cortex may result in soft tissue irritation.
- SP series screws are NOT intended to provide subchondral support and use should be limited to capture of remote bone fragments where partially or fully threaded pegs cannot be used.
- Do NOT permanently implant K-wires through the holes of the plate as they may back out and cause tissue damage. Use of the K-wires allows you to provisionally secure the plates to the anatomy.
- Do NOT use the MDTPs in the distal row of the DVR<sup>®</sup> Anatomic Plate. The MDTPs are intended to be used only with the DVR<sup>®</sup> Anatomic plates. Ensure the MDTPs are installed after insertion of the fixed angle pegs.

## Adverse Effects

The following are possible adverse effects of these implants: potential for these devices failing as a result of loose fixation and/or loosening, stress, excessive activity, load bearing particularly when the implants experience increased loads due to a delayed union, nonunion, or incomplete healing.

*Note: It is NOT required to remove F.A.S.T. Guide™ inserts to sterilize the plate.*



## HAND INNOVATIONS

DNP® Anatomic Plate and DVR® Anatomic Plate are registered trademarks and F.A.S.T. Guide™ is a trademark of DePuy Orthopaedics, Inc.



**DePuy International Ltd**  
St Anthony's Road  
Leeds, LS11 8DT  
England  
Tel: +44 (113) 387 7800  
Fax: +44 (113) 387 7890

**DePuy Orthopaedics, Inc.**  
700 Orthopaedic Drive  
Warsaw, IN 46581-0988  
USA  
Tel: +1 (800) 366 8143  
Fax: +1 (574) 371 4865



0M0000  
XXXX-XX-XXX

Printed in USA.  
©2008 DePuy Orthopaedics, Inc. All rights reserved.